Joint	Joint movement	Muscle responsible	Location
			Anterior forearm 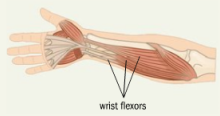
			Posterior forearm 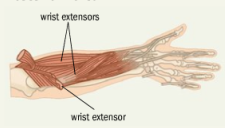

REMEMBER

The wrist joint is a condyloid joint with its articulating bones being the radius, ulna and carpals.

Joint	Joint movement	Muscle responsible	Location
			Superior anterior forearm
			Lateral anterior forearm

REMEMBER

The radio-ulnar joint is a pivot joint with its articulating bones being the radius and ulna.

Joint	Joint movement	Muscle responsible	Location of muscle
			Posterior trunk 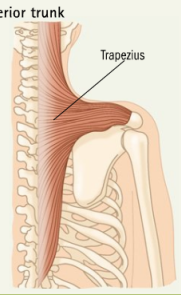
			Attaches back of scapula to humerus 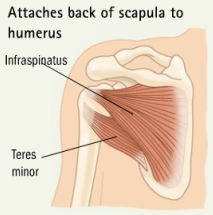
			Attaches side and front of scapula to humerus 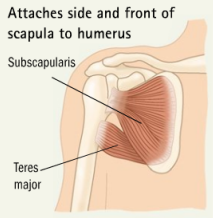

Joint	Joint movement	Muscle responsible	Location of muscle
			Cover anterior tibia 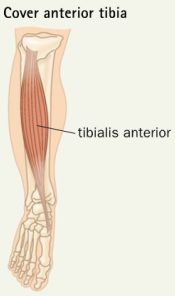
			Calf muscles 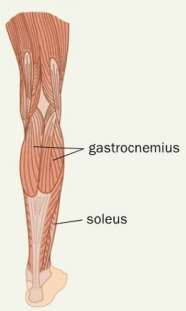

Joint	Joint movement	Muscle responsible	Location of muscle
			Posterior thigh 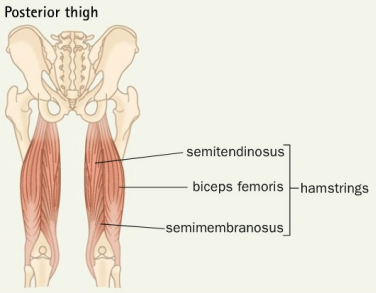
			Anterior thigh 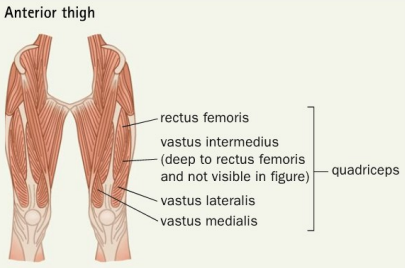

Joint	Joint movement	Muscle responsible	Location of muscle
			Covers shoulder joint 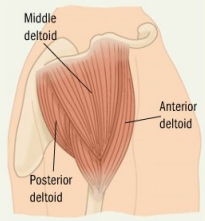
			Posterior trunk 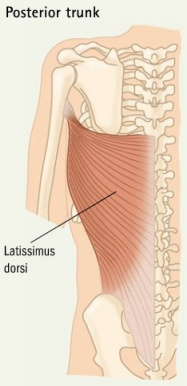
			Top of chest 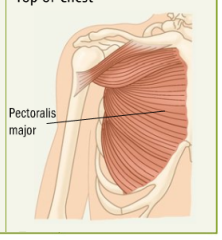

Joint	Joint movement	Muscle responsible	Location of muscle
			Posterior trunk 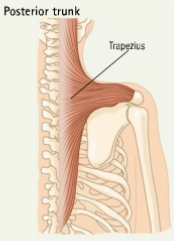
			Attaches back of scapula to humerus 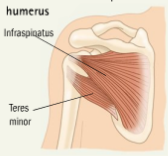
			Attaches side and front of scapula to humerus 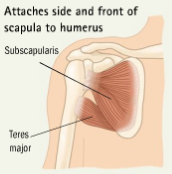

REMEMBER

The spine contains examples of cartilaginous, pivot and gliding joints with its articulating bones being the vertebrae.

REMEMBER

Contraction of one side of the obliques will cause lateral flexion to the same side but rotation to the opposite side.

Joint	Joint movement	Muscle responsible	Location of muscle
			Middle of abdomen 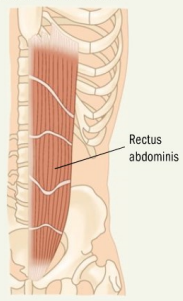
			Covers length of spine 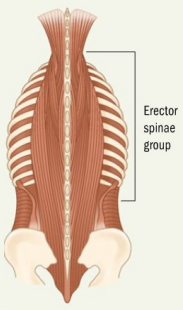
			Lateral abdomen 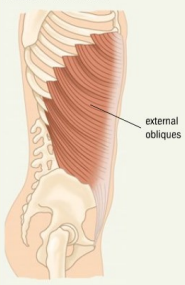
			Lateral abdomen beneath external obliques 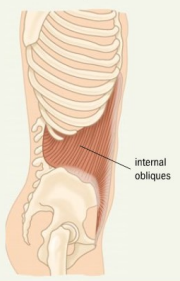

Isotonic contraction		Isometric contraction
Concentric contraction	Eccentric contraction	
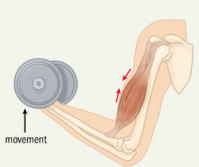	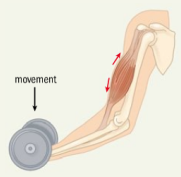	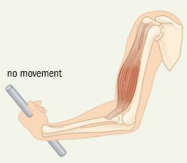
• concentric contraction in the biceps brachii during upward phase of exercise. • the biceps brachii produces tension and *shortens*. • it pulls the forearm upwards to *cause* flexion of the elbow.	• eccentric contraction occurs in the biceps brachii during the downward phase of the exercise. • the biceps brachii produces tension and *lengthens*. • it slows the lowering of the forearm and *controls* extension of the elbow.	• isometric contraction occurs in the biceps brachii when the muscle is holding the weight still. • the biceps brachii develops tension and *stays the same length*. • it *stops* flexion and extension of the elbow.

Joint	Joint movement	Muscle responsible	Location of muscle
			Anterior pelvis 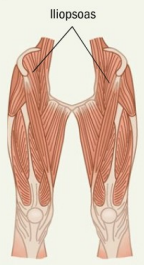
			Posterior pelvis
			Lateral hip (minimus is underneath medius) 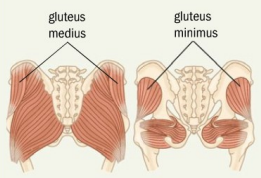
			Medial thigh 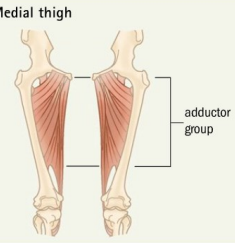

REMEMBER

The gluteus maximus also produces lateral rotation of the hip, while the gluteus minimus produces medial rotation.

Upper limb	Joint movement	Agonist muscle	Antagonist muscle
Wrist joint	Flexion		
	Extension		
Radio-ulnar joint	Pronation joint		
	Supination		
Elbow joint	Flexion		
	Extension		
Shoulder joint	Flexion		
	Extension		
	Horizontal flexion		
	Horizontal extension		
	Abduction		
	Adduction		
	Lateral rotation		
	Medial rotation		
Spine	**Joint movement**	**Agonist muscle**	**Antagonist muscle**
Spine	Flexion		
	Extension		
	Lateral flexion		
	Rotation		
Lower limb	**Joint movement**	**Agonist muscle**	**Antagonist muscle**
Hip joint	Flexion		
	Extension		
	Abduction		
	Adduction		
	Lateral rotation		
	Medial rotation		
Knee joint	Flexion		
	Extension		
Ankle joint	Dorsiflexion		
	Plantar flexion		